



2015 ARDMS Pediatric Echocardiography Job Task Analysis Summary Report

© American Registry for Diagnostic Medical Sonography (ARDMS)

Table of Contents

ABOUT THE REPORT.....	3
METHODOLOGY.....	3
Job Task Analysis (JTA) Working Group.....	3
Survey Administration.....	3
Data Analysis.....	3
SURVEY RESULTS.....	4
Demographics and Backgrounds of Participants.....	4
Gender.....	4
Location of Practice.....	4
Prerequisite.....	4
Profession.....	4
Work Setting.....	4
Lab Size.....	5
Experience and Training.....	5
Task Descriptions.....	7

ABOUT THE REPORT

The American Registry for Diagnostic Medical Sonography (ARDMS) is the globally recognized standard of excellence in sonography. It is responsible for the preparation of valid and reliable certification examinations in sonography. The performance of job task analysis (JTA) at the national level assists ARDMS in evaluating the current practice expectations and performance requirements of the specialty. The 2015 Pediatric Echocardiography (PE) JTA was designed to collect information on the sonography-related work activities sonography registrants actually perform in practice. The results were used in the development of the test content outline that guides content distribution of the PE Examination. This report details the methodology, data collection & analysis and survey results. It also includes the test content outline that resulted from the JTA.

METHODOLOGY

Job Task Analysis (JTA) Working Group

A JTA Working Group consisting of four subject matter experts (SMEs) led this project. All fifteen JTA Working Group members were Exam Development Task Force (EDTF) members and volunteers. Survey Questionnaire Development

ARDMS facilitated a process whereby the JTA Working Group developed the task list and demographic items for the survey. Tasks and demographic items from previous job task surveys were used as a starting point in this development. The JTA Working Group reached a consensus on a list of 105 tasks to be used in the survey. These tasks were divided into six domains: Anatomy and Physiology; Abnormal Pathology and Pathophysiology; Congenital Anomalies; Postoperative (surgically corrected/palliated) Anatomy; Clinical Standards and Guidelines; and Measurement Techniques and Quantification. All task statements and response options were relevant to RDCS credentialed sonographers.

The survey questionnaire was pilot-tested with a group of fifteen individuals from the PE EDTF and volunteers.

Survey Administration

The survey was made available to participants as a web-based survey through the survey platform Qualtrics®. An invitation to participate in the study was sent via email to the members.

ARDMS sent the job task analysis survey to 2,538 registrants credentialed since 2010. These registrants were selected randomly using a stratified sampling method so that the sample is representative of all ARDMS RDCS registrants in terms of specialty, gender, and geographic region. The survey was made available to the participants for four weeks between June 29th and July 17th, 2015. The participants responded anonymously and all responses were kept confidential.

A total of 1381 (54.4% of those sampled) sonographers responded to the survey. Of these, 1261 (49.68%) reported that they are currently performing Pediatric Echocardiography. The data analysis were based on the responses from the 1261 sonographers.

Data Analysis

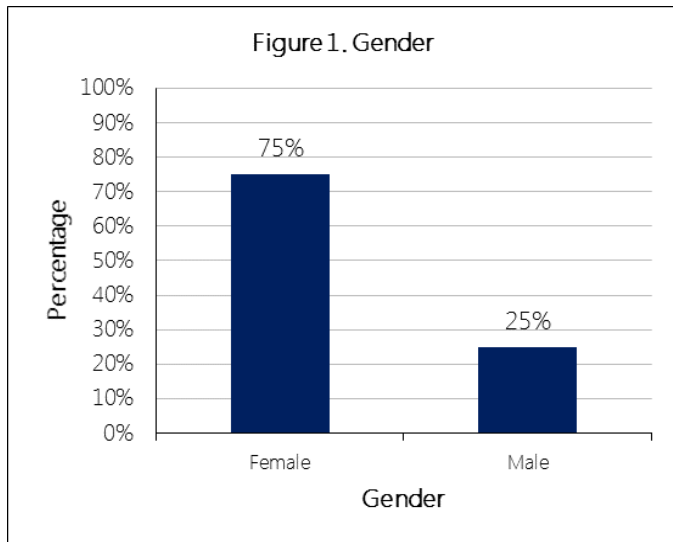
Respondents were asked the following questions for each task: How frequently do you perform the task in your practice, and how important is the task in affecting clinical decisions and patient outcomes? The frequency and importance rating scales were scored 1-5. The response options for the frequency scale were Never, Rarely, Occasionally, Often, and Frequently. The response options for the importance scale were Not Important, Somewhat Important, Moderately Important, Very Important, and Critically Important.

SURVEY RESULTS

Demographics and Backgrounds of Participants

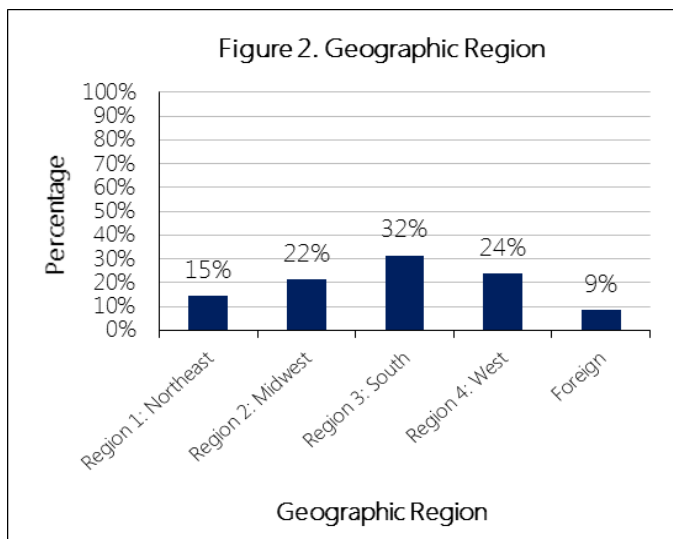
Gender

Approximately 75% of the respondents were female and 25% were male (Figure 1).



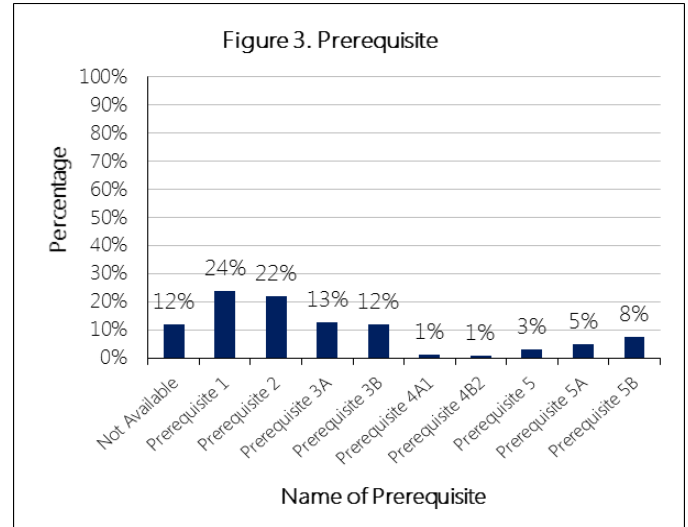
Location of Practice

Most of the respondents reside in the United States. About a third of the respondents practice in the southern region of the United States.(Figure 2).



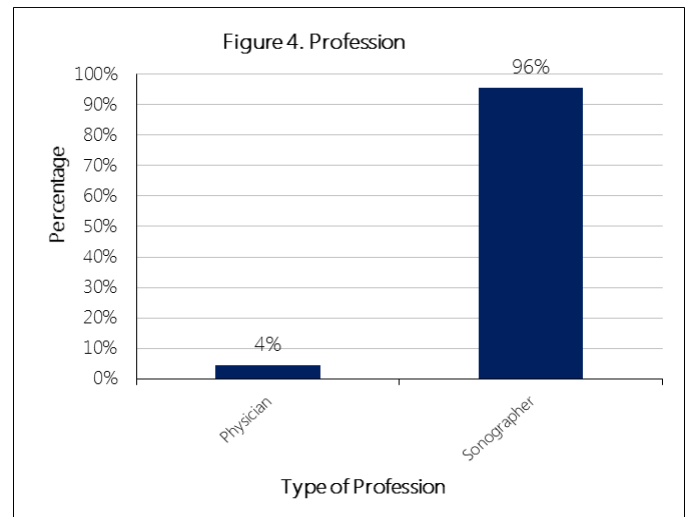
Prerequisite

Approximately one-half of the candidates met eligibility requirements under Prerequisite 1 or Prerequisite 2. The other one-half was spread among eight other prerequisites (Figure 3).



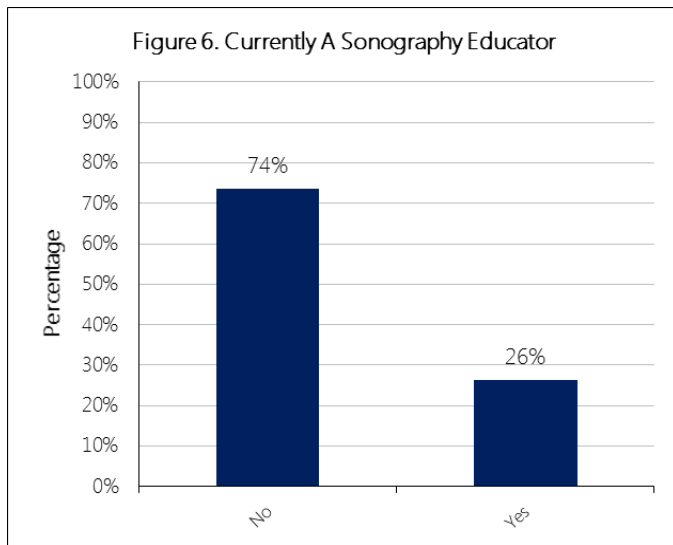
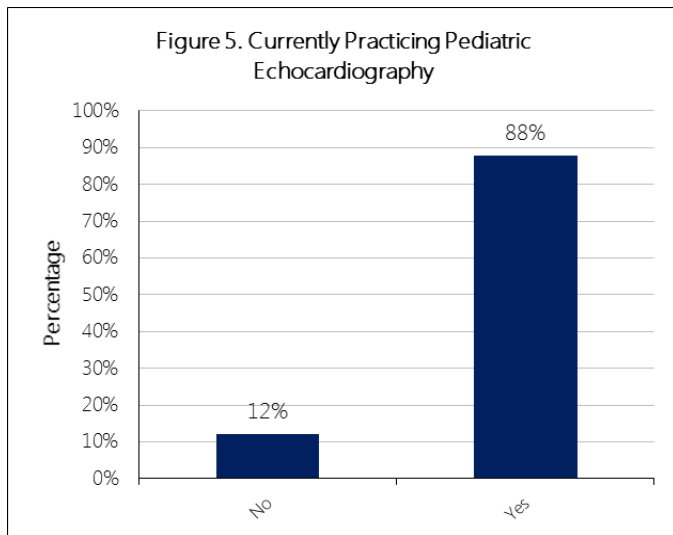
Profession

Approximately 96% of respondents are sonographers and 4% are physicians (Figure 4).

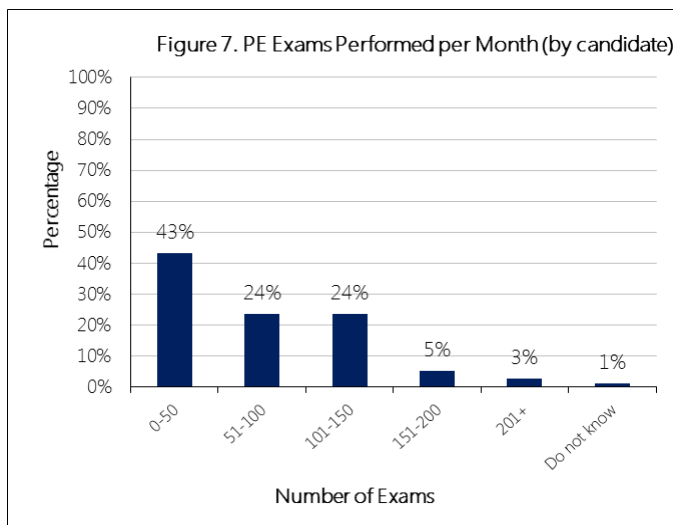


Work Setting

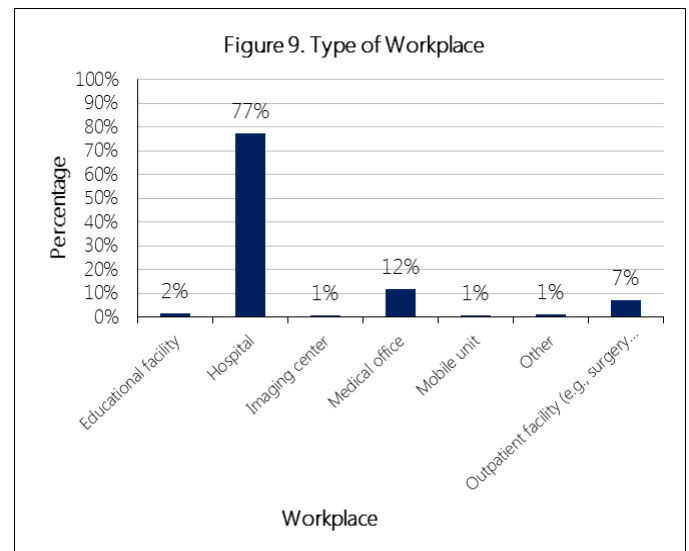
The majority (88%) of respondents are currently practicing Pediatric Echocardiography (Figure 5). Approximately 74% of respondents are currently a sonography educator (Figure 6).



Approximately 43% of the respondents perform 0-50 PE exams per month and about 56% perform more than 50 exams per month (Figure 7).

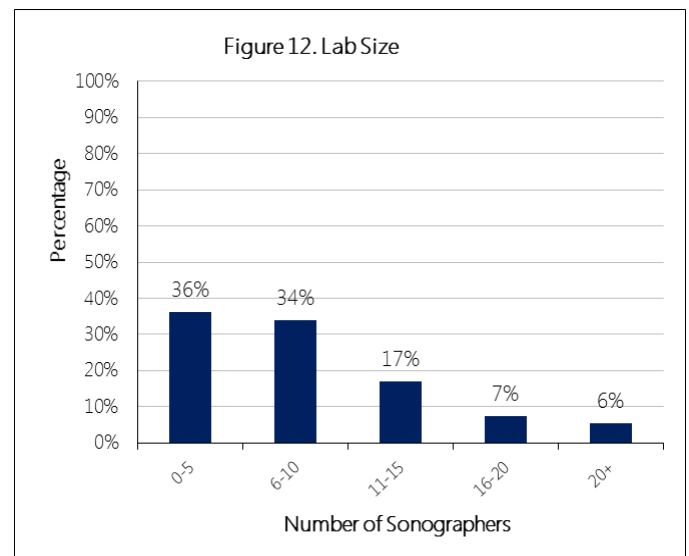


The respondents were asked to indicate the type of environment they perform most of their PE sonographic examinations. The highest frequencies were seen in hospitals (Figure 9).



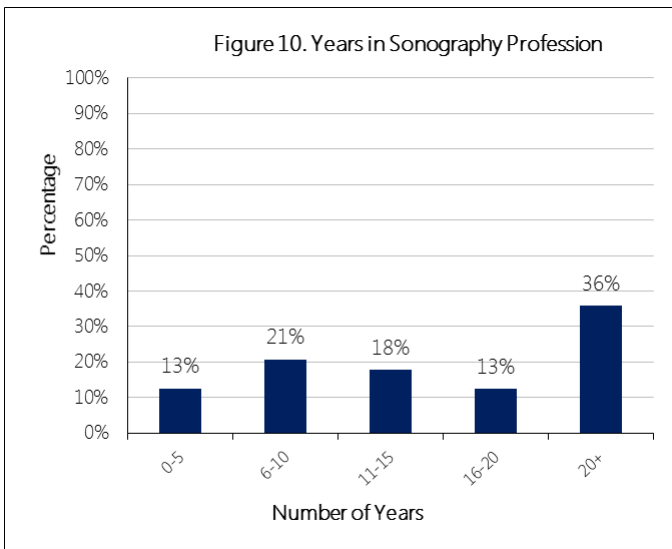
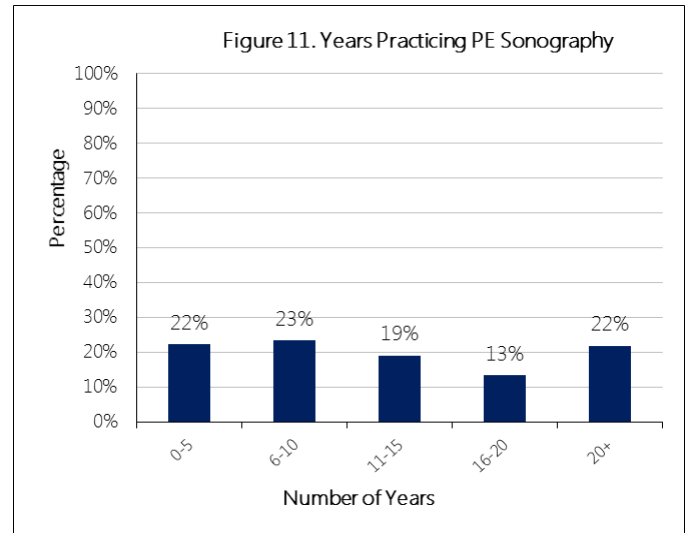
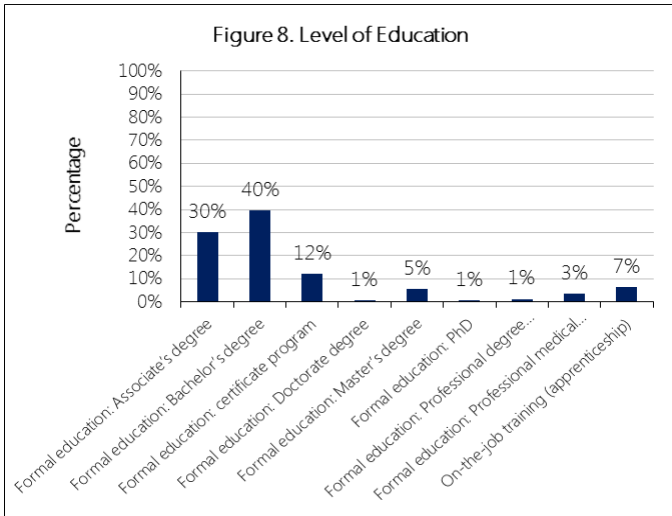
Lab Size

The majority (70%) of the respondents work in labs with 10 or less sonographers (Figure 12).



Experience and Training

Approximately 51% of the respondents have a Bachelor's degree or higher and 30% had an Associate's degree (Figure 8). 13% of the respondents had five years or less of experience in sonography, 52% had 6-20 years of experience and 36% had more than 20 years of experience (Figure 10). Years of practicing PE sonography data is evenly spread out from 0 to 20+ years (Figure 11).



Task Descriptions

Table 3 contains the Task Summary within Domain. Table 4 contains the preliminary and approved domain breakdowns.

Table 3. Task Summary within Domain

Domain, Subdomain, & Task	
Anatomy and Physiology	10%
Normal Anatomy and Physiology	
Identify great artery anatomy and flow patterns (i.e., aorta; aortic arch sidedness and branching; main and branch pulmonary arteries)	
Identify normal valve structure, motion, and flow patterns	
Identify normal ventricular morphology and motion	
Identify normal transitional circulation (e.g., patent foramen ovale [PFO], patent ductus arteriosus [PDA], decreasing pulmonary vascular resistance)	
Identify coronary artery origins, proximal branches, and color flow pattern	
Identify normal systemic and pulmonary venous anatomy and flow patterns (i.e., superior vena cava, inferior vena cava, innominate vein, coronary sinus, azygos vein, pulmonary veins)	
Identify normal abdominal situs and segmental cardiac anatomy	
Identify normal right and left atrial morphology (i.e., eustachian valve, Chiari network, appendages)	
Abnormal Pathology and Pathophysiology	12%
Abnormal Pathology and Pathophysiology	
Assess cardiomyopathies (e.g., dilated, hypertrophic, restrictive)	
Assess findings associated with pulmonary hypertension	
Assess pericardial effusion	
Assess coronary artery abnormalities associated with Kawasaki disease	
Identify findings associated with infective endocarditis (e.g., valvular regurgitation, vegetation, abscess)	
Identify intracardiac and vascular thrombus	
Assess functional abnormalities associated with drug toxicity (e.g., adriamycin chemotherapy)	
Assess findings associated with rheumatic fever	
Assess features associated with cardiac transplantation and rejection	
Assess lesions associated with gestational or maternal diabetes	
Assess pleural effusions	
Identify possible echocardiographic abnormalities associated with systemic hypertension in children	
Identify lesions associated with connective tissue disorders (e.g., Marfan syndrome, Ehlers-Danlos syndrome, Loeys-Dietz syndrome)	
Identify lesions associated with syndromes (e.g., Turner, Williams, DiGeorge, Noonan)	
Identify lesions associated with Down syndrome	
Congenital Anomalies	22%
Congenital Anomalies	
Assess aortic arch anomalies (e.g., coarctation, interruption, anomalous branching patterns)	
Assess conotruncal defects (e.g., tetralogy of Fallot [TOF], double outlet right ventricle [DORV], truncus arteriosus, and aortopulmonary [AP] window)	

Assess abnormalities of the aortic valve

Assess abnormal atrioventricular and ventriculoarterial connections (e.g., dextro-transposition of the great arteries [d-TGA], levo-transposition of the great arteries [l-TGA] or physiologically corrected TGA)

Assess atrioventricular septal defects (e.g., endocardial cushion defect, atrioventricular canal defect)

Assess ventricular outflow tract abnormalities (e.g., subvalvar obstructive lesions)

Assess atrial and ventricular septal defects

Assess pulmonary venous anomalies (i.e., partially and totally anomalous connection/drainage; pulmonary vein stenosis)

Assess pulmonary artery (PA) abnormalities (i.e., supraaortic and peripheral PA stenosis; dilated PAs; discontinuous PAs)

Assess abnormalities of the mitral valve

Assess patent ductus arteriosus and aortopulmonary collaterals

Assess abnormalities of the pulmonic valve

Assess supraaortic stenosis

Assess coronary artery abnormalities (i.e., sinusoids, fistulae, anomalous origins)

Assess abnormalities of the tricuspid valve

Assess abnormalities of abdominal and cardiac situs/position

Assess vascular rings and slings (i.e., double aortic arch, right arch with aberrant subclavian artery, pulmonary sling)

Assess systemic venous anomalies (i.e., interrupted inferior vena cava, bilateral superior vena cava)

Assess cardiac tumors

Assess cor triatriatum

Postoperative (surgically corrected/palliated) Anatomy 20%

Postoperative Anatomy

Assess tetralogy of Fallot repair

Assess valve repair/replacement

Assess surgical repair for coarctation of the aorta

Assess atrial and ventricular septal defect surgical repairs

Assess shunt closure devices (i.e., atrial septal defect, patent ductus arteriosus, and ventricular septal defect devices/coils)

Assess Fontan palliation procedure with and without fenestration

Assess bidirectional Glenn anastomosis

Assess arterial/atrial switch operation

Assess patients after balloon dilation of valves and great vessels

Assess modified Blalock-Taussig shunt or central shunt

Assess Norwood stage 1 procedure and modifications

Assess Ross procedure

Assess repair of total/partial anomalous pulmonary venous connection

Assess pulmonary artery banding

Assess Rastelli repair

Assess implantable devices and lines (e.g., catheters, pacemaker/defibrillator leads, cannulae, stents)

Clinical Standards and Guidelines 8%

Clinical Standards

Obtain a parasternal view (i.e., short axis, long axis, right, high left)
Obtain a suprasternal view (i.e., short axis, long axis)
Obtain an apical view (i.e., two-chamber, three-chamber/long axis, four-chamber with apex down, five-chamber)
Obtain a subcostal view (i.e., sagittal/long axis, coronal/long axis)
Select appropriate settings to optimize image quality and Doppler information
Select appropriate transducer(s) for patient size, window, and modality
Identify imaging artifacts
Measurement Techniques and Quantification 28%
Measurement Techniques
Interrogate the aortic arch using color and spectral Doppler
Interrogate the atrial and ventricular septum using color Doppler
Assess aortic stenosis and grade severity
Interrogate the pulmonary venous return using color and spectral Doppler
Interrogate the pulmonary artery and branches using color and spectral Doppler
Assess right ventricular pressure using tricuspid and pulmonary regurgitant jet velocities
Assess pulmonary stenosis and grade severity
Interrogate systemic venous return using color and spectral Doppler
Assess tricuspid regurgitation and grade severity
Assess aortic regurgitation and grade severity
Analyze ventricular regional wall motion qualitatively using two-dimensional imaging and/or M-mode
Assess mitral regurgitation and grade severity
Assess mitral stenosis and grade severity
Assess ventricular septal defect gradients
Calculate maximal pressure gradients using the modified Bernoulli equation
Assess pulmonary regurgitation and grade severity
Demonstrate echocardiographic findings at specific times during the electrocardiogram (cardiac) cycle
Assess atrial septal shunting gradients
Assess tricuspid stenosis and grade severity
Measure chamber sizes and wall thickness using M-mode
Calculate fractional shortening using M-mode
Perform linear measurements using two-dimensional imaging methods
Calculate ejection fraction using two-dimensional imaging methods
Calculate indices of diastolic function (e.g., E/A ratio, E/E' ratio, mitral valve inflow pattern, pulmonary venous flow pattern)
Measure chamber sizes and wall thickness using two-dimensional imaging methods

Table 4. Content Outline Breakdown by Domain

Domain	Percentage of Examination
Anatomy and Physiology	10%
Abnormal Pathology and Pathophysiology	12%
Congenital Anomalies	22%
Postoperative (surgically corrected/palliated)	20%
Anatomy	8%
Clinical Standards and Guidelines	28%
<i>Total</i>	100%

Note. Forms built to this outline may not match approved percentages exactly.